

HYPAQUE SODIUM- diatrizoate sodium injection, solution
Amersham Health Inc.

HYPAQUE™ Sodium
(Diatrizoate Sodium Injection, USP)
50 %

Sterile Aqueous Injection

For Excretory Urography
Cerebral Angiography
Peripheral Angiography
Aortography
Intraosseous Venography
Direct Cholangiography
Hysterosalpingography
Splenoportography

NOT FOR INTRATHECAL USE

Rx ONLY

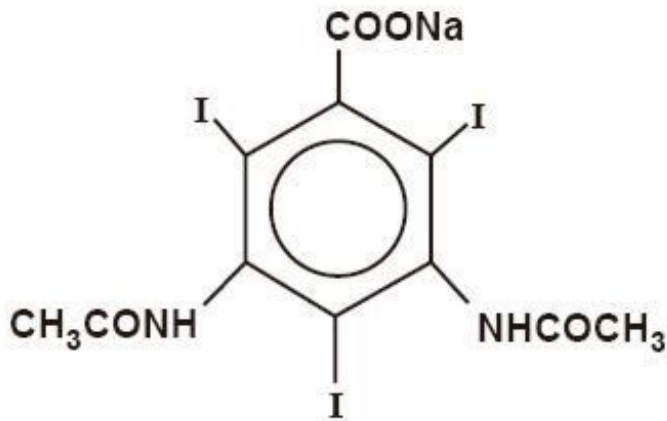
DESCRIPTION

HYPAQUE sodium, brand of diatrizoate sodium, is a radiopaque diagnostic agent, water-soluble organic iodide contrast medium. In pure form, it contains 59.87 percent organically bound iodine.

The 50 percent (w/v) solution contains 300 mg iodine per mL and 0.8 mEq (18.1 mg) sodium per mL. It has an osmolality of 1515 mosm/kg (determined by VPO), and is hypertonic to blood. As a point of information only, a 10 percent solution (w/v) is isotonic. The viscosity (cp) is about 3.25 at 25° C and 2.34 at 37° C. Sodium carbonate and hydrochloric acid have been added to adjust pH between 6.5 and 7.7. The pKa is 3.4 for diatrizoic acid. If a solution of this medium is chilled, crystals may form but readily dissolve if the vial is placed in moderately hot water before use; cool to body temperature before injecting.

The sterile aqueous solution is clear and nearly colorless. It is relatively thermostable and may be autoclaved without harmful effects, although it should be protected from strong light. The 50 percent solution contains edetate calcium disodium 1:10,000 as a sequestering stabilizing agent.

Diatrizoate sodium is a triiodinated benzoic acid derivative, the sodium salt of 3,5-diacetamido-2,4,6-triiodobenzoate with a molecular weight of 635.90, and has the following structural formula:



CLINICAL PHARMACOLOGY

Intravascular injection of a radiopaque diagnostic agent opacifies those vessels in the path of the flow of the contrast medium, permitting radiographic visualization of the internal structures of the human body until significant hemodilution occurs.

At physiologic pH, the water-soluble contrast media are completely dissociated into a radiopaque anion and a solubilizing cation. While circulating in tissue fluids, the compound remains ionized. However, it is not metabolized but excreted unchanged in the urine, each diatrizoate molecule remaining "obligated" to its sodium moiety.

Following intravenous injection, the radiopaque diagnostic agents are immediately diluted in the circulating plasma. Equilibrium is reached with the extracellular compartment at about 10 minutes. Hence, the plasma concentration at 10 minutes is closely related to the dose corrected to body size.

The pharmacokinetics of the intravenously administered radiopaque contrast media are usually best described by a two compartment model with a rapid alpha phase for drug distribution and a slow beta phase for drug elimination. In patients with normal renal function, the alpha and beta half-lives were respectively 30 minutes and 120 minutes for diatrizoate. But in patients with renal functional impairment, the elimination half-life for the beta phase can be prolonged up to several days.

Injectable radiopaque diagnostic agents are excreted either through the liver or through the kidneys. These two excretory pathways are not mutually exclusive, but the main route of excretion seems to be governed by the affinity of the contrast medium for serum albumin. From 0% to 10% of diatrizoate sodium is bound to serum protein.

Diatrizoate salts are excreted unchanged predominantly through the kidneys by glomerular filtration. The amount excreted by the kidney during any period of time is determined by the filtered load; ie, the product of plasma contrast media concentration and glomerular filtration rate. The plasma concentration is dependent upon the dose administered and the body size. The glomerular filtration rate varies with the body size, sex, age, circulatory dynamics, diuretic effect of the drug, and renal function. In patients with normal renal function the maximum urinary concentration of diatrizoate sodium occurs within 10 minutes with 12 percent of the administered dose being excreted. The mean values of cumulative urinary excretion for diatrizoate sodium expressed as percentage of administered dose are 38 percent at 60 minutes, 45 percent at 3 hours, and 94 to 100 percent at 24 hours.

Urinary excretion of contrast media is delayed in infants younger than 1 month and in patients with urinary tract obstruction. The urinary iodine concentration is higher with the sodium salt of diatrizoic acid than with the meglumine salt.

The liver and small intestine provide the major alternate route of excretion for diatrizoate. In patients free of severe renal disease, the fecal recovery is less than 2 percent of the administered dose. In patients with severe renal impairment the excretion of these contrast media through the gallbladder and into the small intestine sharply increases; up to 20 percent of the administered dose has been recovered

in the feces in 48 hours.

Saliva is a minor secretory pathway for injectable radiopaque diagnostic agents. In patients with normal renal function, minimal amounts of contrast media are secreted unchanged. However, in uremic patients small amounts of free iodides resulting from deiodination prior to administration or *in vivo*, have been detected in the saliva.

Diatrizoate salts cross the placental barrier in humans by simple diffusion and appear to enter fetal tissue passively. No apparent harm to the fetus was observed when diatrizoate sodium and diatrizoate meglumine were injected intravenously 24 hours prior to delivery. However, abnormal neonatal opacification of the small intestine and colon were detected 4 to 6 days after delivery. Procedures including radiation involve a certain risk related to the exposure of the fetus. (See **PRECAUTIONS—General, Pregnancy Category C.**)

Injectable radiopaque diagnostic agents are excreted unchanged in human milk. (See **PRECAUTIONS—General, Nursing Mothers.**)

Computerized Tomography

HYPaque sodium 50 percent can be administered as an intravenous bolus for brain tissue enhancement using computerized tomography. Increased tissue contrast differential for the scan is achieved either because of increased vascular (arterial, venous, or capillary bed) contrast or by blood brain barrier penetration of the medium (or its absence) in certain localized areas of disrupted vascular permeability. The degree of tissue enhancement caused by increased blood contrast is directly related to blood iodine content. However, the degree of enhancement due to extravascular accumulation of iodine resulting from blood brain barrier disruption will depend on the extent of disruption, the blood level of iodine, and the time delay prior to scanning. The nature of the pathology will determine whether an immediate or delayed scan is optimal.

Effects of Steroid Therapy

The anti-inflammatory and antiedema effects in patients receiving steroid therapy have interfered with the expected distribution of CT tissue enhancement on the scan in certain diseases.

INDICATIONS AND USAGE

HYPaque sodium 50 percent is indicated for excretory urography, cerebral and peripheral angiography, aortography, intraosseous venography, direct cholangiography, hysterosalpingography, splenoportography, and contrast enhancement of computed tomographic head imaging.

UROGRAPHY

Diatrizoate salts are used in small, medium, and large dose urography (see Dosage and Administration—**EXCRETORY UROGRAPHY**). Visualization of the urinary tract can be achieved by either direct intravenous bolus injection, intravenous drip infusion, or incidentally following intra-arterial procedures. Visualization of the urinary tract is delayed in infants less than 1 month old, and in patients with urinary tract obstruction (see **CLINICAL PHARMACOLOGY**).

CONTRAST ENHANCEMENT OF COMPUTED TOMOGRAPHIC HEAD IMAGING

Injectable radiopaque contrast media may be used to refine diagnostic precision in areas of the brain which may not otherwise have been satisfactorily visualized.

Tumors

Radiopaque diagnostic agents may be useful to investigate the presence and extent of certain malignancies such as: gliomas including malignant gliomas, glioblastomas, astrocytomas, oligodendrogliomas and gangliomas, ependymomas, medulloblastomas, meningiomas, neuromas,

pinealomas, pituitary adenomas, craniopharyngiomas, germinomas, and metastatic lesions.

The usefulness of contrast enhancement for the investigation of the retrobulbar space and in cases of low grade or infiltrative glioma has not been demonstrated.

In calcified lesions, there is less likelihood of enhancement. Following therapy, tumors may show decreased or no enhancement.

The opacification of the inferior vermis following contrast media administration has resulted in false-positive diagnosis in a number of normal studies.

Nonneoplastic Conditions

The use of injectable radiopaque diagnostic agents may be beneficial in the image enhancement of nonneoplastic lesions. Cerebral infarctions of recent onset may be better visualized with contrast enhancement, while some infarctions are obscured if contrast media are used. The use of iodinated contrast media results in contrast enhancement in about 60 percent of cerebral infarctions studied from one to four weeks from the onset of symptoms.

Sites of active infection may also be enhanced following contrast media administration.

Arteriovenous malformations and aneurysms will show contrast enhancement. For these vascular lesions, the enhancement is probably dependent on the iodine content of the circulating blood pool.

Hematomas and intraparenchymal bleeders seldom demonstrate any contrast enhancement. However, in cases of intraparenchymal clot, for which there is no obvious clinical explanation, contrast media administration may be helpful in ruling out the possibility of associated arteriovenous malformation.

ANGIOGRAPHY

Diatrizoate salts are used for radiographic studies throughout the cardiovascular system.

Intravascular radiopaque diagnostic agents of high concentration are not recommended for cerebral or spinal angiography (see **CONTRAINDICATIONS—General**), and contrast agents with the lowest compatible viscosity and higher concentration of iodine (310 mg/mL to 480 mg/mL of bound iodine) must be used for angiocardiology. Contrast media approaching serum ionic content and osmolality have less potential for deleterious effects on the myocardium (see **PRECAUTIONS—General, Drug Interactions**).

Addition of chelating agents may contribute to toxicity in coronary angiography, and the sodium content of angiographic agents used in coronary arteriography is of crucial importance.

In addition to the following general CONTRAINDICATIONS, WARNINGS, PRECAUTIONS, and ADVERSE REACTIONS, there are additional listings in these categories under the particular procedures.

CONTRAINDICATIONS—General

HYPaque sodium 50 percent has no absolute contraindications in its recommended uses (see general WARNINGS and PRECAUTIONS).

Do not use HYPaque sodium 50 percent for myelography or for examination of dorsal cysts or sinuses which might communicate with the subarachnoid space. Even a small amount in the subarachnoid space may produce convulsions and result in fatality. (See also **AORTOGRAPHY, Warnings**.) Epidural injection is also contraindicated.

Urography and large dose vascular procedures are contraindicated in dehydrated azotemic patients. (See also PRECAUTIONS—General.)

WARNINGS—General

SEVERE ADVERSE EVENTS—INADVERTENT INTRATHECAL ADMINISTRATION

Serious adverse reactions have been reported due to the inadvertent intrathecal administration of iodinated contrast media that are not indicated for intrathecal use. These serious adverse reactions include: death, convulsions, cerebral hemorrhage, coma, paralysis, arachnoiditis, acute renal failure, cardiac arrest, seizures, rhabdomyolysis, hyperthermia, and brain edema. Special attention must be given to insure that this drug product is not administered intrathecally.

Ionic iodinated contrast media inhibit blood coagulation, *in vitro*, more than nonionic contrast media. Nonetheless, it is prudent to avoid prolonged contact of blood with syringes containing ionic contrast media.

Serious, rarely fatal, thromboembolic events causing myocardial infarction and stroke have been reported during angiographic procedures with both ionic and nonionic contrast media. Therefore, meticulous intravascular administration technique is necessary, particularly during angiographic procedures, to minimize thromboembolic events. Numerous factors, including length of procedure, catheter and syringe material, underlying disease state and concomitant medications may contribute to the development of thromboembolic events. For these reasons, meticulous angiographic techniques are recommended including close attention to guidewire and catheter manipulation, use of manifold systems and/or three-way stopcocks, frequent catheter flushing with heparinized saline solutions and minimizing the length of the procedure. The use of plastic syringes in place of glass syringes has been reported to decrease but not eliminate the likelihood of *in vitro* clotting.

Excretory urography is potentially hazardous in patients with multiple myeloma. In some of those patients, therapeutically resistant anuria resulting in progressive uremia, renal failure, and eventually death has followed this procedure. Although neither the contrast agent nor dehydration has been proved separately to be the cause of anuria in myelomatous patients, it has been speculated that the combination of both may be causative. The risk of excretory urography in myelomatous patients is not a contraindication to the procedure; however, they require special precautions. Partial dehydration in the preparation of these patients for the examination is not recommended since this may predispose to the precipitation of myeloma protein in the renal tubules. Myeloma, which occurs most commonly in persons over age 40, should be considered before instituting urographic procedures.

Contrast media may promote sickling in individuals who are homozygous for sickle cell disease when the material is injected intravenously or intra-arterially.

Administration of radiopaque materials to patients known or suspected of having pheochromocytoma should be performed with extreme caution. If, in the opinion of the physician, the possible benefits of such procedures outweigh the considered risks, the procedures may be performed; however, the amount of radiopaque medium injected should be kept to an absolute minimum. The blood pressure should be assessed throughout the procedure and measures for treatment of a hypertensive crisis should be available.

Recent reports of thyroid storm occurring following the intravascular use of iodinated radiopaque diagnostic agents in patients with hyperthyroidism or with an autonomously functioning thyroid nodule suggest that this additional risk be evaluated in such patients before use of HYPAAQUE sodium.

Contrast media administered for cardiac catheterization and angiocardiology may cause cellular injury to circulating lymphocytes. Chromosomal damage in humans includes inhibition of mitosis, increases in the number of micronuclei, and chromosome aberrations. The damages appear to be related to the contrast medium itself rather than to the x-ray radiation. It is to be noted that those agents have not been adequately tested in animal or laboratory systems.

Urography should be performed with caution in patients with severely impaired renal function and patients with combined renal and hepatic disease.

Subcutaneous extravasation, chiefly because of hypertonic cellulitis, causes transitory stinging. If the volume extravasated is small, ill effects are very unlikely. However, if the extravasation is extensive

especially in poorly vascularized areas (eg, dorsum of the foot or hand), and especially in the presence of vascular disease, skin slough may occur. Injection of sterile water to dilute or addition of spreading agents to speed absorption have not been successful and may aggravate the condition.

Selective spinal arteriography or arteriography of trunks providing spinal branches can cause mild to severe muscle spasm. However, serious neurologic sequelae, including permanent paralysis, have occasionally been reported. (See also **ANGIOGRAPHY, Precaution.**)

In patients with subarachnoid hemorrhage, a rare association between contrast administration and clinical deterioration, including convulsions and death, has been reported. Therefore, administration of intravascular iodinated ionic contrast media in these patients should be undertaken with caution.

PRECAUTIONS—General

Diagnostic procedures which involve the use of radiopaque diagnostic agents should be carried out under the direction of personnel with the prerequisite training and with a thorough knowledge of the particular procedure to be performed. Appropriate facilities should be available for coping with any complication of the procedure, as well as for emergency treatment of severe reactions to the contrast agent itself. After parenteral administration of a radiopaque agent, competent personnel and emergency facilities should be available for at least 30 to 60 minutes since severe delayed reactions have occurred (see **ADVERSE REACTIONS—General**).

The possibility of a reaction, including serious, life-threatening, fatal, anaphylactic or cardiovascular reactions should always be considered (see **ADVERSE REACTIONS**). It is of utmost importance that a course of action be carefully planned in advance for immediate treatment of serious reactions, and that adequate and appropriate personnel be readily available in case of any reaction.

Preparatory dehydration for angiography and CT procedures is unnecessary and may be dangerous, contributing to acute renal failure in infants, young children, the elderly, patients with preexisting renal insufficiency, patients with advanced vascular disease, and diabetic patients. Dehydration in these patients seems to be enhanced by the osmotic diuretic action of urographic agents. Overnight fluid restriction for urography may be undesirable and is considered unnecessary when using this relatively high (50%) concentration.

Although azotemia is not a contraindication, the medium should be used with great care in patients with advanced renal destruction associated with severe uremia. (See also **EXCRETORY UROGRAPHY, Precautions.**)

Acute renal failure has been reported in diabetic patients with diabetic nephropathy and in susceptible nondiabetic patients (often elderly with preexisting renal disease) following excretory urography. Therefore, careful consideration of the potential risks should be given before performing this radiographic procedure in these patients. (See also **EXCRETORY UROGRAPHY, Precautions—Preparatory Dehydration.**)

Immediately following surgery, excretory urography should be used with caution in renal transplant recipients.

The possibility of an idiosyncratic reaction in susceptible patients should always be considered (see **ADVERSE REACTIONS—General**). The susceptible population includes patients with a history of a previous reaction to a contrast media, patients with a known sensitivity to iodine per se, and patients with a known clinical hypersensitivity: bronchial asthma, hay fever, and food allergies.

The occurrence of severe idiosyncratic reactions has prompted the use of several pretesting methods. However, pretesting cannot be relied upon to predict severe reactions and may itself be hazardous for the patient. It is suggested that a thorough medical history with emphasis on allergy and hypersensitivity, prior to injection of any contrast media, may be more accurate than pretesting in predicting potential adverse reactions.

A positive history of allergies or hypersensitivity does not arbitrarily contraindicate the use of a contrast agent, where a diagnostic procedure is thought essential, but caution should be exercised (see ADVERSE REACTIONS—General). Premedication with antihistamines or corticosteroids to avoid or minimize possible allergic reactions in such patients should be considered. Recent reports indicate that such pretreatment does not prevent serious life-threatening reactions, but may reduce both their incidence and severity.

Due to the transitory increase in the circulatory osmotic load, injections of urographic agents should be used with caution in patients with congestive heart failure. Such patients should be observed for several hours following the procedure to detect delayed hemodynamic disturbances.

General anesthesia may be indicated in the performance of some procedures in young or uncooperative children and in selected adult patients; however, a higher incidence of adverse reactions has been reported in these patients, and may be attributable to the inability of the patient to identify untoward symptoms, or to the hypotensive effect of anesthesia which can reduce cardiac output and increase the duration of exposure to the contrast agent.

Seizure activity is rare (about 0.01%) on intravenous injection of ionic contrast media. However, in the higher doses used for CT in patients with brain metastases the incidence can be much higher (1% to 10%). In these patients prophylactic use of a small parenteral dose of a diazepam is suggested immediately before injection when extra high dose CT regimens are employed.

In addition to the general precautions already described, excretory urography, angiography, and other uses also have hazards associated with the particular techniques employed. (See INDIVIDUAL INDICATIONS AND USAGE section.)

INFORMATION FOR PATIENTS

Patients receiving injectable radiopaque diagnostic agents should be instructed to:

1. Inform the physician if they are pregnant (see CLINICAL PHARMACOLOGY).
2. Inform the physician if they are diabetic or if they have multiple myeloma, pheochromocytoma, homozygous sickle cell disease or known thyroid disorder (see WARNINGS—General).
3. Inform the physician if they are allergic to any drugs, food, or if they have had any reactions to previous injections of dyes used for x-ray procedures (see PRECAUTIONS—General).
4. Inform the physician about any other medications they are currently taking, including nonprescription drugs, before they are administered this drug.

DRUG INTERACTIONS

Renal toxicity has been reported in a few patients with liver dysfunction who were given oral cholecystographic agents followed by urographic agents. Administration of intravascular urographic agents should therefore be postponed in any patient with a known or suspected hepatic or biliary disorder who has recently received a cholecystographic contrast agent.

Addition of an inotropic agent to contrast agents may produce a paradoxical depressant response which can be deleterious to the ischemic myocardium.

Diphenhydramine hydrochloride may cause precipitation when mixed in the same syringe with HYPAQUE sodium 50%.

Under certain circumstances (pH, temperature, concentrations, time), diatrizoate solutions are incompatible with promethazine hydrochloride, diphenhydramine hydrochloride, brompheniramine maleate, or papaverine hydrochloride solutions.

Do not prefill plastic syringes with HYPAQUE sodium 50% for prolonged periods (ie, for several hours or longer) before use.

DRUG/LABORATORY TEST INTERACTIONS

If any of these studies, which might be affected by contrast media are indicated, it is recommended that they be performed prior to administration of the contrast medium or two or more days afterwards.

Diatrizoate salts interfere with several laboratory urine and blood tests.

BLOOD TESTS

Coagulation: Diatrizoate salts significantly inhibit all stages of coagulation. The fibrinogen concentration, Factors V, VII, and VIII are decreased. Prothrombin time and thromboplastin time are increased.

Platelet aggregation: High levels of plasma diatrizoates inhibit platelet aggregation.

Serum calcium: Diatrizoate salts may decrease serum calcium levels. However, this depletion of serum calcium may also be the result of the addition of chelating agents (edetate disodium) in the preparation of certain contrast media.

Red cell counts: Transitory decreases in red cell counts. Technetium-99m—RBC labeling interference.

Leukocyte counts: Decrease.

Urea nitrogen (BUN): Transitory increase (see CLINICAL PHARMACOLOGY).

Serum creatinine: Transitory increase.

URINE TESTS

Contrast media which are excreted in the urine, may interfere with some laboratory determinations eg, proteinuria, specific gravity, osmolality, or bacterial cultures.

THYROID FUNCTION TESTS

Protein-bound iodine (PBI) and total serum organic iodine: Transient increase of both tests following urography have been noticed. The results of PBI and radioactive iodine uptake studies which depend on iodine estimations will not accurately reflect thyroid function for up to 16 days following administration of iodinated urographic media. However, thyroid function tests not depending on iodine estimations, eg, T3 resin uptake or free thyroxine assays are not affected.

CARCINOGENESIS, MUTAGENESIS, IMPAIRMENT OF FERTILITY

Long-term studies in animals have not been performed in order to evaluate carcinogenic potential, mutagenesis, or whether HYPAQUE sodium 50 percent can affect fertility in males or females.

PREGNANCY CATEGORY C

Animal reproduction studies have not been conducted with HYPAQUE sodium 50 percent. It is also not known whether HYPAQUE sodium 50 percent can cause fetal harm when administered to a pregnant woman or can affect reproduction capacity. HYPAQUE sodium 50 percent should be given to a pregnant woman only if clearly needed.

LABOR AND DELIVERY

It is not known whether use of these contrast agents during labor or delivery has immediate or delayed adverse effects on the fetus, prolongs the duration of labor or increases the likelihood that forceps delivery or other obstetrical intervention or resuscitation of the newborn will be necessary.

NURSING MOTHERS

Diatrizoate salts are excreted unchanged in human milk. Because of the potential adverse reactions, although it has not been established that serious adverse reactions occur in nursing infants, caution should be exercised when these contrast media are administered to a nursing woman.

PEDIATRIC USE

Infants and small children should not have any fluid restriction prior to excretory urography or any other procedures (see PRECAUTIONS—General). Guidelines for pediatric dosages are presented in DOSAGE AND ADMINISTRATION—General.

ADVERSE REACTIONS—General

Approximately 95 percent of adverse reactions accompanying the intravascular use of diatrizoate salts are of mild to moderate severity. However, life-threatening reactions and fatalities, mostly of cardiovascular origin, have occurred.

Adverse reactions to injectable contrast media fall into two categories: chemotoxic reactions and idiosyncratic reactions.

Chemotoxic reactions result from the physicochemical properties of the contrast media, the dose, and the speed of injection. All hemodynamic disturbances and injuries to organs or vessels perfused by the contrast medium are included in this category.

Idiosyncratic reactions include all other reactions. They occur more frequently in patients 20 to 40 years old. Idiosyncratic reactions may or may not be dependent on the amount of dose injected, the speed of injection, the mode of injection, and the radiographic procedure. Idiosyncratic reactions are subdivided into minor, intermediate, and severe. The minor reactions are self-limited and of short duration; the severe reactions are life-threatening and treatment is urgent and mandatory.

The reported incidence of adverse reactions to contrast media in patients with a history of allergy are twice that of the general population. Patients with a history of previous reactions to a contrast medium are three times more susceptible than other patients. However, sensitivity to contrast media does not appear to increase with repeated examinations.

Most adverse reactions to injectable contrast media appear within one to three minutes after the start of injection, but delayed reactions may occur.

Adverse reactions are grouped by organ system and listed below by decreasing order of occurrence and with an approximate incidence of occurrence. Significantly more severe reactions are listed before the other reactions regardless of frequency.

GREATER THAN 1 IN 100 PATIENTS

Body as a Whole: Reported incidences of death range from 6.6 per 1 million (0.00066 percent) to 1 in 10,000 patients (0.01 percent). Most deaths occur during injection or 5 to 10 minutes later, the main feature being cardiac arrest with cardiovascular disease as the main aggravating factor. Isolated reports of hypotensive collapse and shock following urography are found in the literature. The incidence of shock is estimated to occur in 1 out of 20,000 (0.005 percent) patients.

Cardiovascular System: The most frequent adverse reaction to diatrizoate salts is vasodilation (feeling of warmth). The estimated incidence is 49 percent.

Digestive System: Nausea 6 percent, vomiting 3 percent.

Nervous System: Paresthesia 6 percent, dizziness 5 percent.

Respiratory System: Rhinitis 1 percent, increased cough 2 percent.

Skin and Appendages: Urticaria 1 percent.

Pain at the injection site is estimated to occur in about 12 percent of the patients undergoing urography. Pain is usually due to extravasation.

Painful hot erythematous swelling above the venipuncture site was estimated to occur in more than one percent of the patients undergoing phlebography.

Special Senses: Perversion of taste 11 percent.

Urogenital System: Osmotic nephrosis of the proximal tubular cells is estimated to occur in 23 percent

of patients following excretory urography.

LESS THAN 1 IN 100 PATIENTS

Other infrequently reported reactions without accompanying incidence rates are listed below, grouped by organ system.

Body as a Whole: Malaria relapse, uremia high creatinine and BUN (see **PRECAUTIONS—General, Drug/Laboratory Test Interactions**), thrombocytopenia, leukopenia, and anemia.

Cardiovascular System: Cerebral hematomas, hemodynamic disturbances, sinus bradycardia, transient electrocardiographic abnormalities, ventricular fibrillation, petechiae, chest pain, cardiac arrest, tachycardia, hypertension, hypotension, and vascular collapse.

Digestive System: Severe unilateral or bilateral swelling of the parotid and submaxillary glands.

Nervous System: Convulsions, paralysis, coma, memory loss. (See **PRECAUTIONS—General.**)

Respiratory System: Asthma, dyspnea, laryngeal edema, pulmonary edema, and bronchospasm.

Skin and Appendages: Extravasation necrosis, urticaria with or without pruritus, mucocutaneous edema, and angioneurotic edema.

Special Senses: Bilateral ocular irritation, lacrimation, itching, conjunctival chemosis, infection, and conjunctivitis.

Urogenital: Renal failure, pain.

OVERDOSAGE

At dosage levels of diatrizoate sodium above a level containing 45 g of iodine, the incidence of unpleasant side effects increases. At total dosage equivalent to 80 gI or 90 gI administered over a short period of time (eg, 30 minutes), clinical signs of systemic intolerance appear (mostly related to hyperosmolar effects) and are manifest as tremors, irritability, and tachycardia. Above these maximal tolerated dosage levels in otherwise healthy adults, an increasing incidence and severity of dyspnea and pulmonary edema should be expected.

Four cases of overdosage in infants, during urography, are reported. Three of the infants died within 19 hours of the injection. The overdose ranged from slightly above the recommended pediatric dosage to a dose exceeding 19 g/kg. The symptoms of overdosage appeared between 10 minutes to several hours after injection of the contrast medium. Adverse effects were life-threatening, affecting mainly the pulmonary and cardiovascular systems. The symptoms included: cyanosis, bradycardia, acidosis, pulmonary hemorrhage, convulsions, coma, and cardiac arrest. All infants showed a poor visualization of the kidneys and a diffuse opacification of all the tissues and vasculature. Autopsy findings showed acute pulmonary damage and/or edema of subcutaneous tissues. Treatment of an overdose of injectable radiopaque contrast media is directed toward the support of all vital functions, and prompt institution of symptomatic therapy.

The acute intravenous LD50 of diatrizoate sodium in mice is equivalent in iodine content of 5.3 gI/kg to 8.0 gI/kg and seem to be directly proportional to the rate of injection.

Diatrizoate sodium is dialyzable.

DOSAGE AND ADMINISTRATION—General

Preparation of the patient will vary with preference of the radiologist and the type of radiological procedure performed. Specific radiologic procedures used will depend on the state of the patient and the diagnostic indications. Individual doses should be tailored according to age, body size, and indication for examination. (See **INDIVIDUAL INDICATIONS AND USAGE** section for specific Dosage and Administration.)

Solutions of radiopaque diagnostic agents for intravascular use should be at body temperature when injected and may need to be warmed before use. In the event that crystallization occurs, the solution may

be clarified by placing the vial in a water bath at 40 ° C to 50 ° C and shaking gently for two to three minutes or until the solids redissolve. If particles still persist, do not use this vial but discard it. The solution should be protected from light and any unused portion remaining in the container should be discarded.

Dilution and withdrawal of the, contrast agents should be accomplished under aseptic conditions with sterile syringes.

Parenteral drug products should be inspected visually for particulate matter and discoloration prior to administration. Avoid contaminating catheters, syringes, needles, and contrast media with glove powder or cotton fibers.

PEDIATRIC DOSAGE

Pediatric doses of injectable radiopaque diagnostic agents are generally determined on a weight basis and should be calculated for each patient individually. (See INDIVIDUAL INDICATIONS AND USAGE section.)

DRUG INCOMPATIBILITIES

Diatrizoate salts are incompatible *in vitro* with some antihistamines and many other drugs. It is believed that one of the chief causes of *in vitro* incompatibility is an alteration of pH. Turbidity of solutions of intravascular contrast medium occurs between pH 2.5 and 4.1. Another cause is chemical interaction; therefore, other pharmaceuticals should not be mixed with contrast agents in the same syringe.

INDIVIDUAL INDICATIONS AND USAGE

THE FOLLOWING SECTIONS FOR INDIVIDUAL INDICATIONS AND USAGE CONTAIN CONTRAINDICATIONS, WARNINGS, PRECAUTIONS, ADVERSE REACTIONS, AND DOSAGE AND ADMINISTRATION SECTIONS RELATED TO THE SPECIFIC PROCEDURES. HOWEVER, IT SHOULD BE UNDERSTOOD THAT THE INFORMATION IN THE GENERAL SECTIONS IS ALSO LIKELY TO APPLY TO ALL OF THESE SPECIFIC USES.

Hydration—With the possible exception of urography, patients should be fully hydrated prior to the following procedures.

EXCRETORY UROGRAPHY

Dehydration (fluid deprivation for 12 to 15 hours) improves urographic contrast especially at lower dosage level (see PRECAUTIONS—General). A preparatory laxative at bedtime to reduce gas and feces is often employed.

Diatrizoate salts are used in small, medium, and large dose urography. (See **Dosage and Administration—EXCRETORY UROGRAPHY**.) Visualization of the urinary tract can be achieved by either direct intravenous bolus injection, intravenous drip infusion, or sometimes by intramuscular or subcutaneous injections, or incidentally following intra-arterial procedure.

In infants less than 1 month only visualization of the urinary tract is delayed, therefore the number of roentgen exposures during the early part of the examination should be limited.

In patients with substantially impaired renal function and in patients with urinary tract obstruction, optimal visualization may be delayed for as long as 60 minutes or more. In such patients large doses may be required for adequate urograms.

For distribution and excretion of diatrizoates, see CLINICAL PHARMACOLOGY.

CONTRAINDICATION

Urography is contraindicated in patients with anuria.

PRECAUTIONS

See PRECAUTIONS—General. Some clinicians consider multiple myeloma a contraindication to excretory urography because of the great possibility of producing transient to fatal renal failure. Others believe that the risk of causing anuria is definite but small. If excretory urography is performed in the presence of multiple myeloma, dehydration should be avoided since it favors protein precipitation in renal tubules.

Although azotemia is not considered a contraindication, care is required in patients with advanced renal failure. The usual preparatory dehydration should be omitted, and urinary output should be observed for one to two days in these patients. Adequate visualization may be difficult or impossible to attain in patients with severely impaired renal and/or hepatic function. Use with extreme caution in patients with concomitant hepatorenal disease.

Preparatory Dehydration

Preparatory dehydration is dangerous in infants, young children, the elderly, and azotemic patients (especially those with polyuria, oliguria, diabetes, advanced vascular disease, or preexisting dehydration). The undesirable dehydration in these patients may be accentuated by the osmotic diuretic action of the medium.

Dehydration may improve image quality in patients with adequate renal function particularly if a low dose is used. Dehydration, however, will not improve contrast quality in patients with substantial renal insufficiencies and will increase risk of contrast induced renal damage. Dehydration in these patients is therefore contraindicated.

ADVERSE REACTIONS

See ADVERSE REACTIONS—General.

DOSAGE AND ADMINISTRATION

INTRAVENOUS DOSAGE

Adults. A dose of 30 mL of the 50 percent solution administered intravenously with or without compression produces diagnostic shadows in the majority of adults subjected to partial dehydration and to effective purgation. If the administration of 30 mL does not provide satisfactory visualization, this dose may be repeated in 15 to 30 minutes. In persons of slight build 20 mL may produce adequate shadows.

Larger doses ranging from 50 mL to 60 mL of the 50 percent solution may be used for routine excretory urography in adults. The increased dosage offers better and more complete visualization of the urinary tract. This technique requires neither compression nor dehydration and is more effective in obese patients. Adverse reactions to the larger dose are similar to those encountered with lower doses without an increase in incidence, severity, or type of reactions. Voiding cystourethrograms may be obtained when desired. For the best results and minimal side effects, it is advisable to inject the total amount of solution intravenously in one to three minutes.

Children. The dosage of the 50 percent solution for children under 6 months of age is 5 mL; for children 6 to 12 months of age, 6 mL to 8 mL; for children 1 to 2 years of age, 8 mL to 10 mL; for children 2 to 5 years of age, 10 mL to 12 mL; for children 5 to 7 years of age, 12 mL to 15 mL; for children 7 to 11 years of age, 15 mL to 18 mL, and for children 11 to 15 years of age, 18 mL to 20 mL.

Subcutaneous or Intramuscular Urography

HYPaque sodium 50 percent may be used for excretory urography via intramuscular injection, undiluted or diluted; or subcutaneously diluted with equal quantities of sterile water for injection.

The intramuscular injection site generally used is the gluteal muscles in two separate, equal doses. Used subcutaneously the medium is generally injected in divided equal doses over each scapula.

In both locations the contrast medium is rapidly absorbed providing urograms beginning variously 5 to 10 minutes following intramuscular injection; subsequent exposures being made according to degree of pyelographic contrast.

Radiographs with subcutaneous injection are usually exposed at 10, 20, and 30 minutes. The urograms achieved with either methods will be almost equal to that following intravenous injection.

The usual intramuscular or subcutaneous (diluted) dose of HYPAAQUE sodium 50 percent in adults and older children is about 20 mL to 30 mL. For infants and young children, the dose ranges from 5 mL to 16 mL.

Roentgenography

A plain film is often made prior to IVP. A nephrogram effect is available in 30 to 60 seconds. Its duration is dose dependent.

Urograms may be available as early as two minutes. However, urograms of optimal density are usually made at 5, 10, or 15 minutes following injection.

Ureteric films are usually made between 10 and 20 minutes, and cystograms at 30 minutes. In impaired renal function, delayed films may be required.

ANGIOGRAPHY

Angiography should be avoided whenever possible in patients with homocystinuria, because of the risk of inducing thrombosis and embolism.

CEREBRAL ANGIOGRAPHY

HYPAAQUE sodium 50 percent may be administered for visualization of the cerebral vessels. In as much as cerebral angiography is a highly specialized procedure requiring the use of special techniques, it is recommended that HYPAAQUE sodium 50 percent be used for this purpose only by persons skilled and experienced in carrying out the procedure.

CONTRAINDICATION

Carotid angiography during the progressive period of a stroke should be avoided, particularly on the left side because of the increased risk of cerebral complications.

PRECAUTIONS

See PRECAUTIONS—General. Patients in whom cerebral angiography is to be performed should be selected with care.

Although cerebral angiography has been considered contraindicated in patients who have recently experienced cerebral embolism or thrombosis (stroke syndrome), many experts now believe that the diagnostic value of the procedure, when employed early as an aid in locating lesions amenable to operation, outweighs any added risk to the patient. Furthermore, a small number of postangiographic fatalities have been reported, including progressive thrombosis already clinically evident before angiography, in which the procedure did not appear to play any direct role. Patients with severe cerebrovascular disease should be examined primarily by indirect methods of angiography.

In cerebral angiography, every precaution must be taken to prevent untoward reactions. Reactions may vary directly with the concentration of the substance, the amount used, the speed and frequency of injections, and the interval between injections.

In subarachnoid hemorrhage, angiography is expected to be hazardous. In migraine, the procedure can

be hazardous because of ischemic complications, particularly if performed during or soon after an attack.

ADVERSE REACTIONS

See ADVERSE REACTIONS—General. With any contrast medium introduced into the cerebral vasculature, neurologic complications, including neuromuscular disorders, seizures, loss of consciousness, hemiplegia, unilateral dysesthesias, visual field defects, language disorders (aphasia), amnesia, and respiratory difficulties may occur, particularly when the extent of the intrinsic lesion is unknown. Such untoward reactions are for the most part temporary, although permanent visual field defects have been reported. Some investigators who are experienced in angiographic procedure emphasize the fact that they tend to occur after repeated injections or higher doses of the contrast medium. Other clinicians find that they occur most frequently in elderly patients. In as much as the procedure itself is attended by technical difficulties regardless of the risk the patient presents (eg, mechanical catheter obstruction of the vertebral artery can cause transient blindness), the more experienced the radiologic team, the fewer the complications of any degree that are apt to arise.

Amaurosis can occur following carotid or especially selective vertebral arteriography. It is almost always transitory (4 to 48 hours).

DOSAGE AND ADMINISTRATION

A dose of 8 mL to 12 mL injected at a rate not exceeding the normal flow in the carotid artery (about 5 mL per second) is suggested. The dose may be repeated as indicated; however, an increased risk attends each repeat injection. In the retrograde brachial or catheter method (aortic arch), a single injection of 35 mL to 50 mL is generally used. Children require a smaller dose in proportion to weight. Light anesthesia may be required in these procedures.

PERIPHERAL ANGIOGRAPHY

HYPaque sodium 50 percent may be administered for peripheral arteriography and for venography.

PRECAUTIONS

See PRECAUTIONS—General. Extreme caution is advised in considering peripheral arteriography in patients suspected of having thromboangiitis obliterans (Buerger's disease) since any procedure (even insertion of a needle or catheter) may induce a severe arterial or venous spasm. Caution is also advisable in patients with severe ischemia associated with ascending infection.

ADVERSE REACTIONS

See ADVERSE REACTIONS—General. Soreness in extremities has also been reported.

Adverse reactions observed during peripheral arteriography may sometimes be due to arterial trauma during the procedure (ie, insertion of needle or catheter, subintimal injection, perforation) as well as to the hypertonicity or effect of the medium. Reported adverse reactions include transient arterial spasm, extravasation, hemorrhage, hematoma formation with tamponade, injury to nerves in close proximity to artery, thrombosis, dissecting aneurysm, arteriovenous fistula (eg, with accidental perforation of femoral artery and vein during the needling), and transient leg pain from contraction of calf muscles in femoral arteriography. Transient hypotension has been reported after intra-arterial (brachial) injection of the medium. Also, brachial plexus injury has been reported with axillary artery injections.

During venography in the presence of venous stasis, inflammatory changes and thrombosis may occur. Thrombosis is rare if the vein is irrigated following the injection.

DOSAGE AND ADMINISTRATION

Diagnostic arteriograms may be obtained with 25 mL to 35 mL of HYPaque sodium 50 percent introduced into the larger peripheral arteries by percutaneous or operative methods. Visualization of

veins in the extremities may be accomplished with 15 mL to 40 mL.

AORTOGRAPHY

HYPAAQUE sodium 50 percent may be administered intravenously or intra-arterially by accepted techniques to visualize the aorta and its major branches.

WARNINGS

Pheochromocytoma. Administration of angiographic media to patients known or suspected to have pheochromocytoma can cause dangerous changes in blood pressure. A minimum dose should be injected. The blood pressure should be carefully monitored and measures for controlling major fluctuations should be available.

During aortography by the translumbar technique, extreme care is advised to avoid inadvertent intrathecal injection since the injection of even small amounts (5 mL to 7 mL) of the contrast medium may cause convulsions, permanent sequelae, or fatality. Should the accident occur, the patient should be placed upright to confine the hyperbaric solution to a low level, anesthesia may be required to control convulsions, and if there is evidence of a large dose having been administered, a careful cerebrospinal fluid exchange-washout should be considered.

PRECAUTIONS

The presence of a vigorous pulsatile flow should be established before using a catheter or pressure injection technique. A small "pilot" dose (about 2 mL) should be administered to locate the exact site of needle or catheter tip to help prevent injection of the main dose into a branch of the aorta or intramurally. In the translumbar technique, severe pain during injection may indicate intramural placement and abdominal or back pain afterwards may indicate hemorrhage from the injection site. Following catheter procedures, gentle pressure hemostasis for 5 to 10 minutes is advised, followed by observation for 30 to 60 minutes and immobilization of the limb for several hours to prevent hemorrhage from the site of arterial puncture.

The care and experience with which the procedure is performed, the amount and type of medium used, the age and condition of the patient, and the premedication and anesthesia employed, influence the incidence and severity of reactions or complications that may be encountered. Since aortography is not without some danger, it should be employed only by persons experienced in the technique.

Repeated injections of the solution during a single study should be avoided whenever possible.

Under conditions of slowed aortic circulation there is an increased likelihood of aortography causing muscle spasm. Occasional serious neurologic complications, including paraplegia, have also been reported in patients with aortic-iliac or even femoral artery bed obstruction, abdominal compression, hypotension, hypertension, spinal anesthesia, injection of vasopressors to increase contrast, and low injection sites (L2-3). In these patients the concentration, dose, and number of repeat injections of the medium should be maintained at a minimum with appropriate intervals between injections. The position of the patient and catheter tip should be carefully evaluated.

Aortic Branches. Since serious neurologic complications, including quadriplegia, have occasionally been reported following spinal arteriography or selective injection of arterial trunks providing spinal artery branches (usually the thyrocervical, costocervical, subclavian, vertebral, bronchial, intercostal), great care is necessary to avoid entry of a large concentrated bolus of the medium. Thus, a "pilot" dose may establish correct position of the catheter tip. The concentration of the medium should not be over 50 percent. The carefully individualized dose is usually under 5 mL but preferably 3 mL to 4 mL and the number of repeat injections held to a minimum with appropriate intervals between injections. Pain or muscle spasm during the injection may require reevaluation of the procedure.

ADVERSE REACTIONS

The most common reaction to the medium is a mild burning sensation on injection. In addition to the reactions described in the general section, the following have been reported: mesenteric and intestinal necrosis, acute pancreatitis, renal shutdown (usually transitory), and neurologic complications following inadvertent injection of a large part of the aortic dose into a branch of the aorta. Entry of the large aortic dose into the renal artery can cause, even in the absence of symptoms, albuminuria, cylindruria, and hematuria, and an elevated BUN. Rapid and complete return of function usually follows. Also reported are coronary occlusion, hemorrhage from puncture site, arterial perforation by catheter or needle, thrombosis, embolism, and subintimal injection with aortic dissection by the medium.

DOSAGE AND ADMINISTRATION

The amount of each individual dose is a more important consideration than the total dosage used. Sufficient time should elapse between each injection to allow for subsidence of hemodynamic disturbances.

Retrograde (catheter) aortography—For **adults** and **children**, 0.5 mL to 1 mL per kg of bodyweight.

Intravenous aortography—For **adults** and **children**, 1 mL per kg of body weight.

Translumbar aortography—For **adults**, 10 mL to 30 mL. For **children** under 12 years, the dose is proportionate to age.

Selective renal arteriography—For **adults** and **children** over 14 years of age, 5 mL to 8 mL with repeat injections as indicated. For **younger children**, the dose is proportionate to age.

INTRAOSSEOUS VENOGRAPHY

The 50 percent solution may be injected directly into the bone marrow in the study of venous circulation of the bone and extraosseous tissue in the immediate drainage area.

A general anesthetic is sometimes necessary since the method is painful. Occasionally, extravasation of the contrast medium from the needle into the soft tissue may occur.

DOSAGE AND ADMINISTRATION

After aspiration of 4 mL of marrow, 10 mL to 20 mL of the medium are injected.

To visualize the pterygoid venous plexus, 5 mL to 8 mL of the contrast medium are injected into the medullary cavity of the mandible.

DIRECT CHOLANGIOGRAPHY

PRECAUTION

In the presence of acute pancreatitis, direct cholangiography, if necessary, should be employed with caution, injecting no more than 5 mL to 10 mL without undue pressure.

ADVERSE REACTION

Adverse reactions may often be attributed to injection pressure or excessive volume of the medium, resulting in overdistention. Such pressure may produce a sensation of epigastric fullness, followed by moderate pain in the back or right upper abdominal quadrant, which will subside when injection is stopped.

Hepatobiliary reflux of the medium may cause a pancholangitis or hepatitis which is usually transitory. Retrograde spread of the infection may produce liver abscess or septicemia. Pancreatic duct reflux may cause a transitory increase in serum amylase for a period of 6 to 18 hours without ill effects. Rarely it may cause pancreatitis.

DOSAGE AND ADMINISTRATION

The solution should be warmed to body temperature before administration. The injection is made slowly without undue pressure, taking great care to avoid introducing bubbles.

Operative—If no resistance is encountered, from 10 mL to 15 mL of a 25 percent to 50 percent solution is injected or instilled into the cystic duct or common bile duct, as indicated. In patients with obstructive jaundice, 40 mL to 50 mL of the medium may be injected directly into the gallbladder after aspiration of its contents.

Postexploratory or completion T tube cholangiography may also be performed after exploration of the common bile duct.

Postoperative—Delayed cholangiograms are usually made from the fifth to the tenth postoperative day prior to removal of the T tube.

In case of a dilated ductal tract, a larger volume (up to 100 mL) of radiopaque medium may be required for complete filling and visualization.

PERCUTANEOUS TRANSHEPATIC CHOLANGIOGRAPHY

Percutaneous transhepatic cholangiography is recommended for carefully selected patients for the differential diagnosis of jaundice due to extrahepatic biliary obstruction or parenchymal disease. The procedure is only employed where oral or intravenous cholangiography and other procedures have failed to provide the necessary information. In obstructive cases, percutaneous transhepatic cholangiography is used to determine the cause and site of the obstruction to help plan surgery. The technique may also be of value in avoiding laparotomy in poor risk jaundice patients since failure to enter a duct suggest hepatocellular disease. Careful attention to technique is essential for the success and safety of the procedure. The procedure is usually performed under local anesthesia following analgesic premedication (eg, 100 mg meperidine intramuscularly).

CONTRAINDICATIONS

Percutaneous transhepatic cholangiography is contraindicated in patients with coagulation defects and prolonged prothrombin times until normal, or near normal, coagulation is achieved, eg, with vitamin K.

PRECAUTIONS

Percutaneous transhepatic cholangiography should only be attempted when compatible blood for potential transfusions is in readiness and emergency surgical measures are available. The patient should be carefully monitored for at least 24 hours to insure prompt detection of bile leakage and hemorrhage. Cholespastic premedication, as with morphine, should be avoided. Respiratory movements should be controlled during introduction of the needle.

ADVERSE REACTIONS

In percutaneous transhepatic cholangiography, some discomfort is common, but severe pain is unusual. Complications of the procedure are often serious and have been reported in four to six percent of patients. These reactions have included bile leakage and peritonitis, which are more likely to occur in patients with obstructions that cause unrelieved high biliary pressure. Bleeding (sometimes massive with exsanguination) may occur, especially in patients with clotting abnormalities. Blood-bile fistula, manifested by an early urogram (within 2 minutes), has been reported. Hypotension with fever and chills, as manifestations of septicemia, have occurred. Tension pneumothorax, cholangitis, and bacteremia have been reported.

DOSAGE AND ADMINISTRATION

As the needle is advanced or withdrawn, a bile duct may be located by frequent aspiration for bile or mucus into syringe filled with normal saline. As much bile as possible is aspirated. The usual dose of HYPaque sodium 50 percent is 20 mL to 40 mL but the range can be from 10 mL to 60 mL depending on degree of biliary dilatation present. The injection may be repeated for exposures in different planes.

If a duct is not readily located by aspiration, entry may be established by injection of successive small doses of 1 mL to 2 mL of the medium under x-ray observation as the needle is withdrawn. If a duct is not located after three or four attempts, the procedure should be abandoned. Inability to enter a duct strongly suggests hepatocellular disease.

HYSTEOSALPINGOGRAPHY

Hysterosalpingography may be performed with either the 50 percent solution, or if a somewhat more viscous solution is preferred, diatrizoate meglumine and diatrizoate sodium, 90 percent.

CONTRAINDICATIONS

The procedure should not be performed during the menstrual period or when menstrual flow is imminent, nor should it be performed when infection is present in any portion of the genital tract, including the external genitalia. The procedure is also contraindicated for pregnant women or for those in whom pregnancy is suspected. Its use is not advised for six months after termination of pregnancy, or 30 days after conization or curettage.

PRECAUTION

In patients with carcinoma or in those in whom the condition is suspected, caution should be exercised to avoid possible spread of the lesion by the procedure.

ADVERSE REACTIONS

Cramping may occur during the injection and sometimes mild lower abdominal pain may be present for an hour or two afterwards. Even when the medium gains entrance into venous or lymphatic channels, systemic effects are rare. Generalized urticaria or slight transient hyperpyrexia, however, has been reported.

DOSAGE AND ADMINISTRATION

Preparation of the Patients

It is preferable to perform the procedure approximately 10 days after the patient's menstrual period.

The patient should empty the bladder before the examination. An enema and vaginal douche are not essential but may be given one hour before the study. Premedication is not necessary.

Approximately 4 mL will suffice to fill a normal uterine cavity, with an additional 3 mL or 4 mL for the fallopian tubes. These amounts may vary depending on the nature of the disease.

SPLENOPORTOGRAPHY

INDICATION

Splenoportography is usually performed under mild preoperative sedation and under local anesthesia.

CONTRAINDICATIONS

Splenoportography should not be performed on any patient for whom splenectomy is contraindicated, since complications of the procedure at times make splenectomy necessary. Other contraindications include prolonged prothrombin time or other coagulation defects, significant thrombocytopenia, and any condition which may increase the possibility of rupture of the spleen.

Precautions

Prior gastrointestinal x-ray examination should include particular attention to the lower esophageal area. A hematologic survey, including prothrombin time and platelet count, should be performed. To minimize risk of bleeding, manipulation during or after entry of the needle should be avoided. Caution is

advised in patients whose spleen has recently become tender and palpable.

Following splenoportography, the patient should lie on his left side for several hours and should be closely observed for 24 hours for signs of internal bleeding.

Adverse Reactions

Internal bleeding is the most common serious complication of splenoportography. Although leakage of up to 300 mL of blood is apparently not uncommon, sometimes blood transfusions and rarely, splenectomy, may be required to control hemorrhage. Peritoneal extravasation may cause transient diaphragmatic irritation or mild to moderate transient pain which may sometimes be referred to the shoulder, the periumbilical region, or other areas. Because of the proximity of the pleural cavity, accidental pneumothorax has been known to occur. Inadvertent injection of the medium into other nearby structures is not likely to cause untoward consequences.

Dosage And Administration

A preliminary small "pilot" dose is injected to confirm splenic entry, followed usually by rapid injection of 20 mL to 25 mL of HYPAQUE sodium 50 percent. Rapid serial exposures are started with the injection of the dose and continued until contrast is observed in the entire portal system.

CONTRAST ENHANCEMENT OF COMPUTED TOMOGRAPHIC HEAD IMAGING

Precautions

Metastatic Brain Lesions: Large doses of contrast media should be avoided in patients with suspected metastatic brain lesions. Intravenous administration of large doses to these patients is more likely to result in convulsions; however, these occurrences are rare. This has been attributed to tissue accumulation of the medium in the presence of blood brain barrier disruption caused by disease. Appropriate measures for seizure management should be immediately available.

Convulsion: (See PRECAUTIONS—General).

Dosage And Administration

Bolus intravenous injection of 50 mL to 100 mL, or up to 150 mL by infusion. The rate of injection and the timing of scans will depend principally on the expected nature of the pathology. Dosage in children is proportional to adults, based on weight.

HOW SUPPLIED

Vials of 50 mL, rubber stoppered, box of 25 (NDC 0407-0766-04).

Protect from light. Store at 15°C to 30°C (59° F to 86°F).

Distributed by Amersham Health Inc.
Princeton, NJ 08540

Printed in USA

HNC-7F

HYPAQUE SODIUM

diatrizoate sodium injection, solution

Product Information

Product Type

HUMAN PRESCRIPTION DRUG

Item Code (Source)

NDC:0407-0766

Route of Administration	INTRAVENOUS
--------------------------------	-------------

Active Ingredient/Active Moiety

Ingredient Name	Basis of Strength	Strength
Diatrizoate Sodium (UNII: V5403H8VG7) (Diatrizoic acid - UNII:5UVC90J1LK)		500 mg in 1 mL

Inactive Ingredients

Ingredient Name	Strength
Iodine (UNII: 9679TC07X4)	300 mg in 1 mL
Sodium ()	18.1 mg in 1 mL

Packaging

#	Item Code	Package Description	Marketing Start Date	Marketing End Date
1	NDC:0407-0766-04	25 in 1 BOX		
1		50 mL in 1 VIAL		

Labeler - Amersham Health Inc.

Revised: 4/2006

Amersham Health Inc.